

Two individuals with features of both xeroderma pigmentosum and trichothiodystrophy highlight the complexity of the clinical outcomes of mutations in the *XPD* gene

Bernard C. Broughton, Mark Berneburg¹, Heather Fawcett, Elaine M. Taylor, Colin F. Arlett, Tiziana Nardo², Miria Stefanini², Emory Menefee³, Vera H. Price³, Sophie Queille⁴, Alain Sarasin⁴, Elisabeth Bohnert⁵, Jean Krutmann¹, Rosemarie Davidson⁶, Kenneth H. Kraemer⁷ and Alan R. Lehmann*

Genome Damage and Stability Centre, University of Sussex, Falmer, Brighton BN1 9RR, UK, ¹Clinical and Experimental Photodermatology, Heinrich-Heine-Universität, Moorenstrasse 5, 40225 Düsseldorf, Germany, ²Istituto di Genetica Biochimica ed Evolutionistica CNR, Via Abbiategrosso 207, Pavia, Italy, ³Trichos Research, 5313 Rosalind Avenue, Richmond, CA 94805, USA, ⁴Laboratory of Molecular Genetics, UPR 2169-CNRS, BP 8, 94801, Villejuif, France, ⁵Facultät für Klinische Medizin Mannheim der Universität Heidelberg, 68135 Mannheim, Germany, ⁶Department of Medical Genetics, Yorkhill NHS Trust, Glasgow G3 8SJ, UK and ⁷Basic Research Laboratory, National Cancer Institute, Bethesda, MD 20892, USA

Received July 2, 2001; Revised and Accepted August 23, 2001

The xeroderma pigmentosum group D (*XPD*) protein is a subunit of transcription factor TFIIH with DNA helicase activity. TFIIH has two functions, in basal transcription and nucleotide excision repair. Mutations in *XPD* that affect DNA repair but not transcription result in the skin cancer-prone disorder, xeroderma pigmentosum (XP). If transcription is also affected, the result is the multi-system disorder trichothiodystrophy (TTD), in which there is no skin cancer predisposition, or in rare cases, XP combined with Cockayne syndrome. Up till now there have been no reports of combined clinical features of XP and TTD. We have now identified two patients with some features of both these disorders. One of these, XP189MA, a 3-year-old girl with sun sensitivity, mental and physical developmental delay, has *XPD* mutations not previously reported, and barely detectable levels of nucleotide excision repair. The other, XP38BR, a 28-year-old woman with sun sensitivity, pigmentation changes and skin cancers typical of XP, has a mutation that has been identified previously, but only in TTD patients with no features of XP. The level of repair of UV damage in XP38BR is substantially higher than that in other patients with the same mutation. With both patients, polarized light microscopy revealed a 'tiger-tail' appearance of the hair, and amino acid analysis of the hairshafts show levels of sulfur-containing

proteins intermediate between those of normal and TTD individuals. Our findings highlight the complexities of genotype–phenotype relationships in the *XPD* gene.

INTRODUCTION

Nucleotide excision repair (NER) is the process with which cells are able to remove bulky lesions produced in DNA by UV light or chemical carcinogens. It is a complex process, requiring the products of approximately 30 genes in eukaryotes. Three genetic diseases are associated with defects in NER: xeroderma pigmentosum (XP), Cockayne syndrome (CS) and trichothiodystrophy (TTD). XP can result from mutations in any one of seven NER genes (*XPA* through *G*), and is characterized by photosensitivity, freckling of the skin, increased premalignant skin lesions and a 1000-fold elevated incidence of skin tumours (1–3). In contrast, TTD is characterized by brittle, sulfur-deficient hair that has a 'tiger-tail' appearance under polarizing light, mental and growth retardation, abnormal facies, and in many cases, photosensitivity, but no significant pigmentation changes and no predisposition to skin cancers (4). Most repair-deficient TTD patients are mutated in the *XPD* gene (5), and a further two patients with the combined features of XP and CS are also defective in the *XPD* gene (6,7). Clues to these unexpected findings that mutations in the *XPD* gene can give rise to distinct clinical phenotypes (XP with skin disease; XP with skin and neurologic disease; XP/CS complex; and TTD) (8,9) came from the discovery that the *XPD* (as well as the *XPB*) protein was a subunit of the basal transcription

*To whom correspondence should be addressed. Tel: +44 1273 678120; Fax: +44 1273 678121; Email: a.r.lehmann@sussex.ac.uk
The authors wish it to be known that, in their opinion, the first two authors should be regarded as joint First Authors

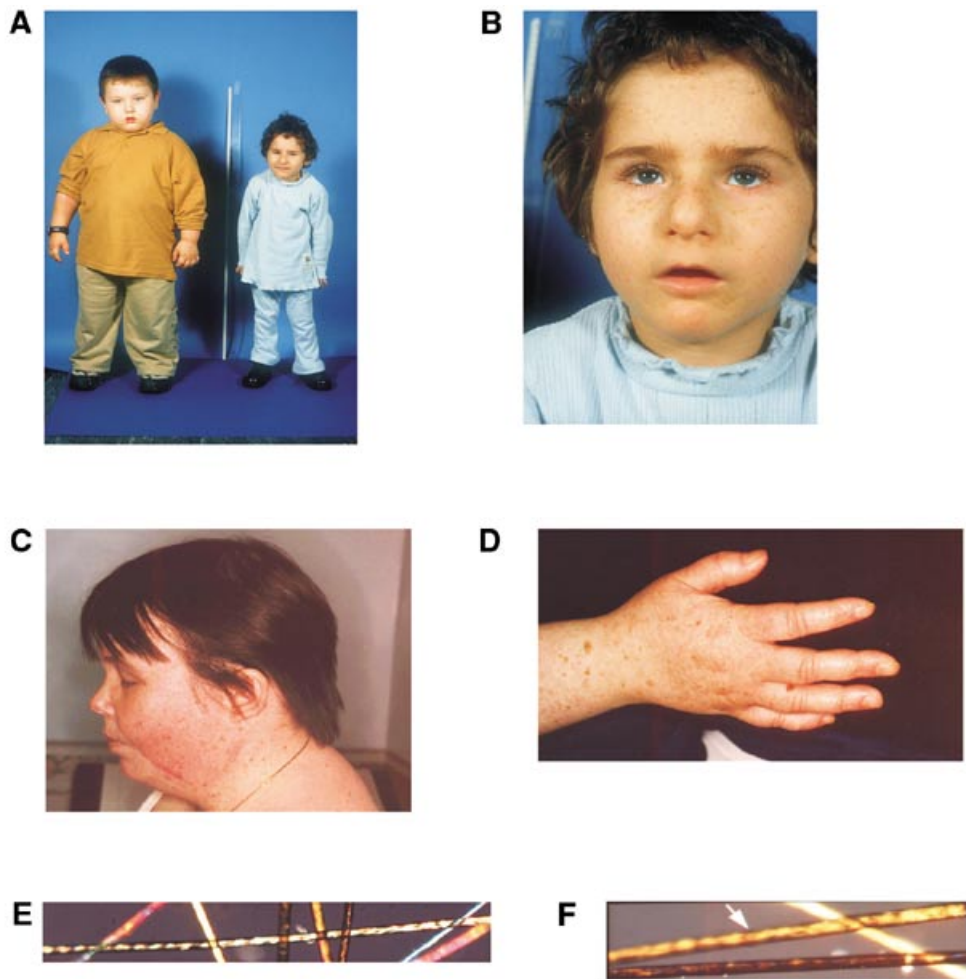


Figure 1. Clinical features of patients. (A) XP189MA, aged 2, and her unaffected twin brother, showing her reduced stature. (B) Face of XP189MA, showing freckling. (C) Face, and (D) hands of XP38BR, at age 27. Note the extensive freckling on sun-exposed skin, the long hair and the finger nails. The scar on her cheek is the site of excision of a squamous cell carcinoma. (E and F) Tiger-tail appearance of the hair shafts. Hairs of the patients were examined using a microscope with polarized light. Alternating light and dark 'tiger-tail' transverse bands are apparent. (E) XP189MA; (F) XP38BR.

factor TFIIH (10,11). Therefore, TFIIH has two distinct roles in the cell, in NER and basal transcription (9,12). Bootsma and Hoeijmakers (13) proposed that mutations affecting only the repair function of TFIIH result in the XP phenotype, whereas mutations affecting the repair and transcription abilities result in TTD. In support of this idea, Taylor *et al.* (14) found that the sites of the mutations in the *XPD* gene were disease specific, i.e. the same mutations were never found in an XP and a TTD patient. Furthermore, a mouse was generated with an *XPD* mutation (Arg722→Trp) that had been found in five TTD patients. The mouse had many of the features of TTD (15).

Curiously, despite similar repair deficiencies in some TTD and XP-D cell lines, TTD patients never have the skin pigmentation abnormalities and greatly increased incidence of skin cancers that are seen in XP individuals. Individuals with the features of both XP and TTD have never been reported. We have proposed that the postulated subtle transcriptional deficiencies in TTD prevent a crucial step in the development of skin cancers (9,16). In this paper, we present an analysis of

two individuals, who, in contrast to all previously reported cases, do have some of the features of both XP and TTD.

RESULTS

Clinical descriptions

Patient XP189MA, the daughter of non-consanguineous German and Italian parents, was referred at age 2.5 with a history of photosensitivity. At birth she was underweight (940 g) and small (36 cm) with size and weight below the third percentile. Neonatal growth was also impaired (less than the third percentile). Upon referral she presented with growth retardation, microcephaly and mental retardation, remaining under the third percentile for growth and mental development (Fig. 1A). The face was dysmorphic with deep-set eyes, mongoloid features and increased freckling on sun exposed areas (Fig. 1B). The skin on the trunk was dry and flaky. There were no signs of actinic keratoses or skin cancer. The hair was full

with a straw-like appearance. Episodes of hair loss had not been observed, and the hair was not brittle.

The skull X-ray was normal, as was the CAT scan, with no signs of abnormal myelination, brain atrophy, calcification or altered ventricular size. Eye examination revealed no abnormalities of the retina or other portions of the eye. There was no deafness and her deep tendon reflexes were normal. Phototesting revealed a highly increased sensitivity towards UV-B light (minimal erythema dose 12 mJ/cm² after 24 h, normal: 75–100 mJ/cm²) and no pigmentary reaction after 30 J/cm² of UV-A.

Patient XP38BR is a 28-year-old woman with a history since early life of photophobia and photosensitivity leading to blistering of the skin and swelling of her eyes on minimal sun exposure. She is the first of four children of non-consanguineous Scottish parents. On examination, she had mild to moderate learning difficulties, obesity, short stature with a height at age 23 of 142 cm (less than the third percentile), and microcephaly with a head circumference of 49.8 cm (less than the third percentile). She was slightly dysmorphic with clustered, small facial features, short palpebral fissures and brachycephaly, as well as relative limb shortening. There was no deafness or retinal abnormality and her deep tendon reflexes were normal. Her skin was dry with extensive freckling, naevi, some on her back being dysplastic, solar keratoses, and pigmentation on sun-exposed areas (Fig. 1C and D). At the age of 23 she developed a squamous cell carcinoma on her face, which was subsequently removed (Fig. 1C). She also had a basal cell carcinoma of her upper lip shortly after this. A solar keratosis was removed at age 25. Apart from her learning difficulties, she had no obvious neurological abnormalities. Her chromosomes were normal. These features are consistent with a diagnosis of XP.

She also had features not normally associated with XP. At the age of three, she lost all her hair, but it subsequently grew back. It is now sparse. She has marked hyperkeratosis of the soles of her feet and dry, glistening, scaling palms. These may be manifestations of palmar-plantar hyperkeratosis. Her fingers are tapered and the nails have longitudinal streaks and are bent at the distal ends (Fig. 1D), but neither hair nor nails appear to be brittle. She is now obese and has had oligomenorrhoea and persistent leukopenia from the age of 14. At the age of 21 she developed insulin-dependent diabetes.

Responses to UV damage

Cells from NER-deficient patients are hypersensitive to killing by UV irradiation and deficient in repair synthesis as measured by unscheduled DNA synthesis (UDS) after UV irradiation. Primary skin fibroblasts from both XP38BR and XP189MA were considerably more sensitive to UV-C-induced lethality than normal cells, XP189MA being more sensitive (Fig. 2A). Likewise, the rates of RNA synthesis were severely reduced in both cell strains following UV-C irradiation. Again XP189MA was more severely affected (Fig. 2B). The levels of UDS were ~30% of normal in XP38BR cells and undetectable in XP189MA, within the limits of our assay (Fig. 2C). These data show that both cell strains are deficient in NER, and suggest that the deficiency in XP189MA is greater than in XP38BR. In order to determine the complementation group to which the cells could be assigned, fibroblasts from each patient were

fused with cells from different XP complementation groups, and UDS was measured. Fusion of XP38BR with XP-B and XP-G cell strains resulted in substantial restoration of UDS (Fig. 2D). In contrast, there was no restoration when XP38BR was fused with XP17PV, from the XP-D group (Fig. 2D). Similarly, fusion of XP189MA with XP-C and XP-G cells restored close to normal UDS, whereas it remained reduced when the cells were fused with XP3NE from group D (data not shown). These results assigned both XP38BR and XP189MA to the XP-D group.

UV-induced apoptosis

High doses of UV light result in apoptosis in normal human fibroblasts. This apoptotic response is generated at much lower doses in NER-deficient XP cells including those from group D, in which the maximal response is seen after 5 J/m² UV-C (Fig. 2E). TTD fibroblast strains with lower UV sensitivity than XP-D cells have a corresponding intermediate dose-response (maximum at 20 J/m² UV-C) (17). We found that the apoptotic dose-response of XP38BR cells was quite similar (albeit somewhat reduced) to that of the TTD cell strain TTD3VI, corresponding to their similar sensitivity to killing by UV-C. We have obtained similar data with exposure of both fibroblasts and keratinocytes from XP38BR to UV-B irradiation (data not shown).

Mutation analysis of the XPD cDNA

We have previously used RT-PCR followed by direct sequencing to determine the sites of the mutations in a large number of XP and TTD patients in the XP-D group (14,18,19). We carried out this analysis on RNA extracted from both XP38BR and XP189MA, and identified the mutations in the XPD cDNA. Both patients were compound heterozygotes. In XP189MA the first allele contained a -2 frameshift with the loss of two Ts at nucleotides 1781–1782 (Fig. 3A) [using the numbering of Weber *et al.* (20), in which the initiation codon ATG is at nucleotide 80]. The frameshift occurs at codon 568 and the altered reading frame immediately runs into a stop codon. This truncation of the C-terminal 192 amino acids (of the 760 amino acid XPD protein) resulting in loss of more than one quarter of the protein, is very likely to destroy the function of the XPD protein. The second allele had a complex alteration with deletion of nucleotides 1823–1825 (AGA) and insertion of TTTCGG at this site (Fig. 3A). The net result is an in-frame alteration of codons 582 and 583 and the insertion of a new glu codon, such that the amino acid sequence is changed from ...VALEKYQ... to ...VALVSEYQ.... XPD is a DNA helicase (21) and has seven highly conserved domains characteristic of DNA helicases (20). The altered amino acids are in a conserved sequence immediately upstream of helicase domain V of the XPD protein (20). The AL and Y residues immediately flanking the altered amino acids are completely conserved in XPD orthologues from 11 species, the altered E residue is present in eight of these, whereas the K is present in only five (human, mouse, hamster, fish, *Caenorhabditis elegans*) (Fig. 3B, middle column). This alteration is likely to have a severe effect and accounts for the complete abolition of UDS in these cells. However, since the cells are obviously viable, the mutation must have only a minor effect on transcription function. Neither of the mutations identified in XP189MA has been

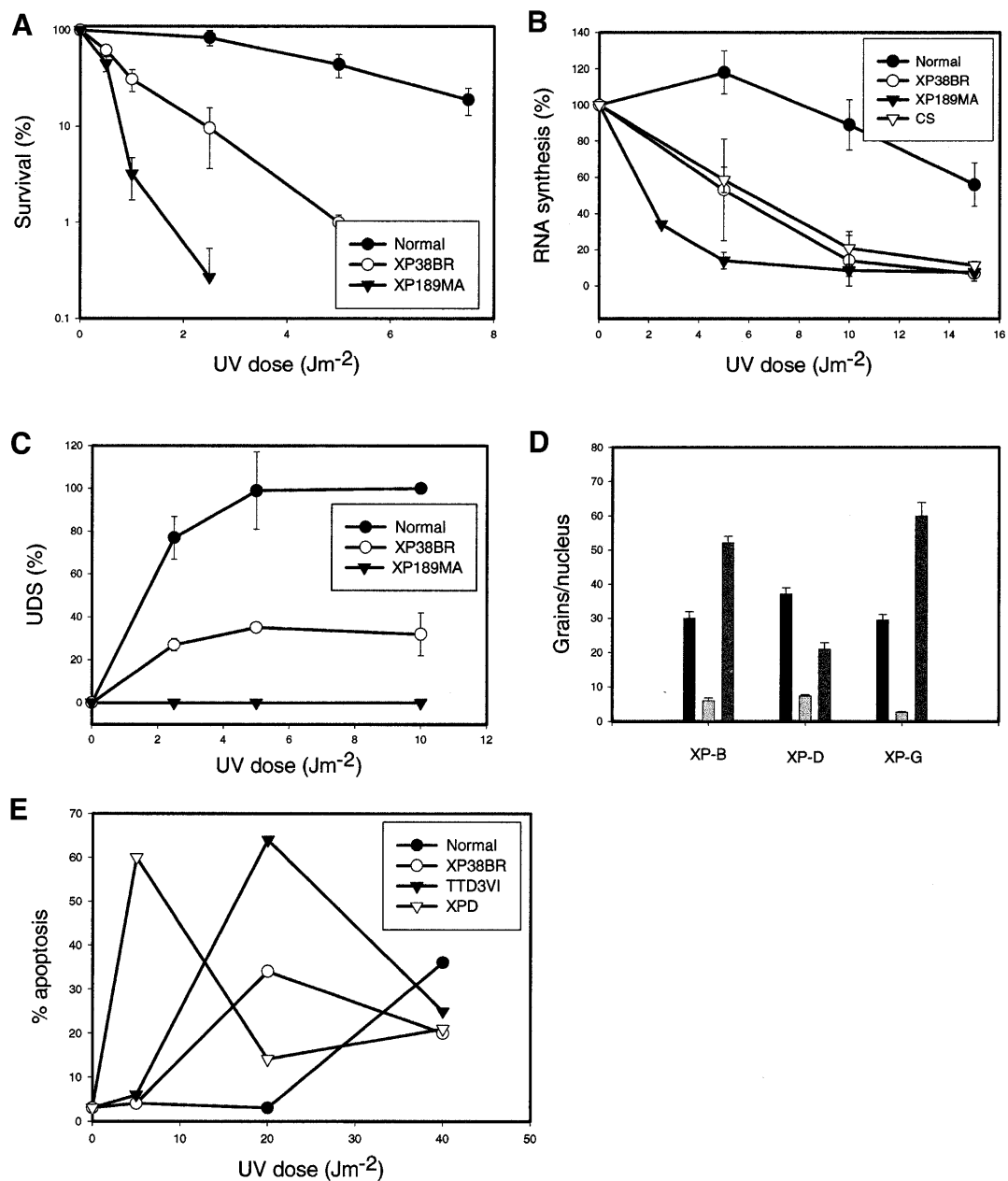


Figure 2. Response of cells to UV-C irradiation. (A) UV survival. Cells were exposed to different doses of UV-C irradiation, and the survival was measured using colony-forming ability. (B) Recovery of RNA synthesis. Twenty four hours after UV irradiation RNA synthesis was measured by the incorporation of ³H-uridine. Results are expressed as percent of incorporation in unirradiated cells. (C) Unscheduled DNA synthesis. NER was measured as the incorporation of ³H-thymidine into non-dividing cells following UV irradiation. Results are expressed as percent of incorporation in normal cells exposed to 10 J/m². (D) Complementation analysis of XP38BR. XP38BR cells were fused with XPCS2BA (XP-B), XP17PV (XP-D) and XP20BE (XP-G) and UDS was measured in binucleate cells after UV irradiation. Each group of three sets of data shows UDS in binucleate homokaryons of XP38BR (left), of its fusion partner (middle), and heterokaryons containing a nucleus from each donor (right). Normal cells analysed in parallel showed a mean number of 84 ± 4 grains per nucleus. (E) Apoptosis. Cells were UV-C-irradiated, incubated for 72 h and the percentage of apoptotic cells was estimated from measuring the sub-G1 peak. The normal cells used in (A)–(C) were 1BR and 48BR. Results from these donors have been combined. In (E), normal fibroblasts were from foreskin.

reported previously in other patients. By carrying out a similar analysis on cDNA from both parents, we have found that the 2 bp deletion is on the maternal allele and the in-frame insertion/deletion on the paternal allele (data not shown). In both XP189MA and her mother the allele containing the 2 bp deletion is present in the amplified cDNA at much lower levels than the other allele.

In our analysis of XP38BR, we were surprised to find that one of the alleles contained the mutation G413A (Fig. 3C, left) causing the alteration Arg112→His. This mutation has been found previously in nine patients, all with the clinical features of TTD (14,18,19), yet the major features of XP38BR were of XP. The second allele contained the mutation T1532C (Fig. 3C, right) resulting in Leu485→Pro, which has not been detected

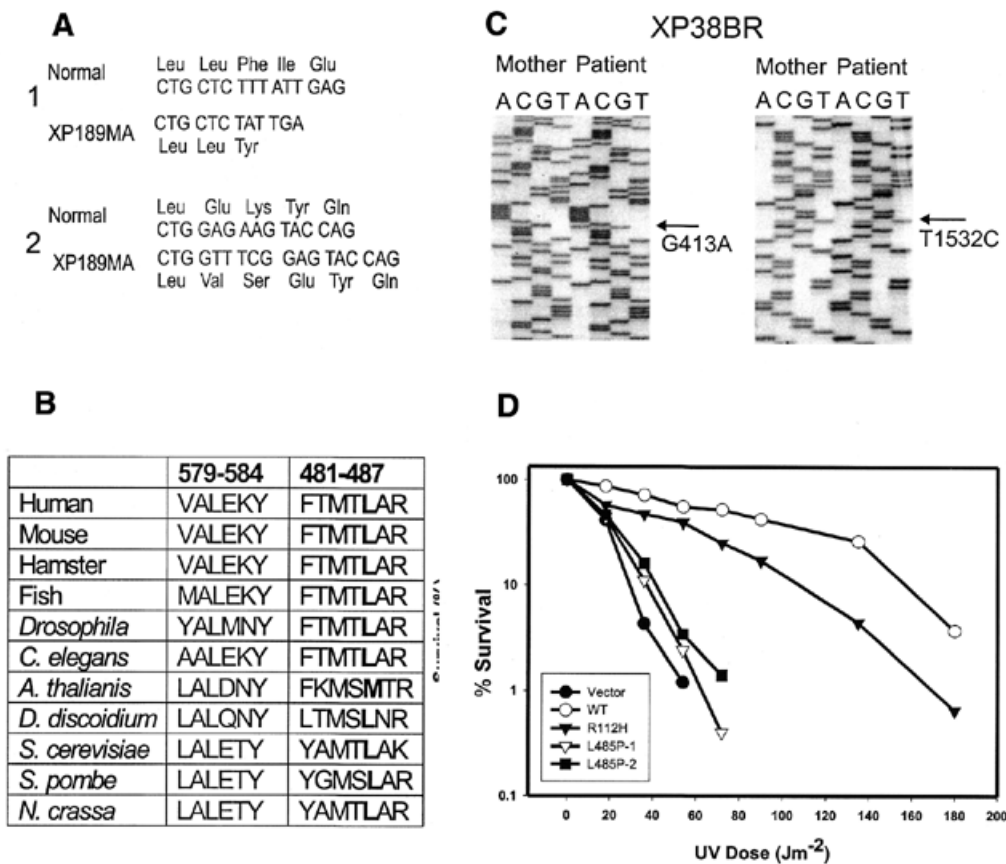


Figure 3. Mutation analysis of the *XPD* gene. (A) Mutations in the two alleles of XP189MA, and the resulting changes in the amino acid sequence of the *XPD* protein. (B) Evolutionary conservation of the sequence altered in the second allele of XP189MA (second column) and in XP38BR (third column). (C) Sequence analysis of the *XPD* cDNA in XP38BR. Note the heterozygous G413A change in XP38BR but not in her mother (left), whereas the heterozygous T1532C is seen in both XP38BR and her mother. (D) Biological analysis of the individual alleles in *S.pombe*. *Schizosaccharomyces pombe rad15.P* mutant cells were transformed with plasmids containing different *rad15* inserts. The ability of the resulting transformants to survive after UV-C irradiation was measured. Two independent transformants of the Leu485→Pro plasmid were analysed.

in other patients reported to date. Leu485 is in a well conserved region between helicase domains II and IV and is conserved in nine out of 10 species (Fig. 3B, third column). We were able to obtain material from the mother but not the father of XP38BR. Sequence analysis showed that XP38BR inherited the Leu485→Pro, but not the Arg112→His alteration from her mother (Fig. 3C), the latter presumably being transmitted from her father. The analysis of the *XPD* cDNA from the mother confirmed that the two mutations were on separate alleles.

We and others have previously identified common polymorphisms in the *XPD* gene (22,23). The particular polymorphic forms of the gene in the two patients are indicated in Table 1. Both patients appear to be homozygous at all four loci, but the polymorphic form is opposite in the two patients.

All previously identified patients with the Arg112→His alteration had unambiguous clinical features of TTD with no hint of XP features. Some of these were homozygous for this mutation, others were compound heterozygous, but functionally hemizygous since the second allele was either shown or anticipated to be completely inactive (14,19). All of them had low levels of UDS (10% of normal) (19). Therefore, we thought that some of the features of XP38BR might result from

Table 1. Polymorphisms in the *XPD* gene

Polymorphic change	A546C	G1012A	C2211T	A2329C
Amino acid change	Arg156→Arg	Asp312→Asn	Asp711→Asp	Lys751→Gln
XP189MA ^a	AA	GG (Asp)	CC	AA (Lys)
XP38BR ^a	CC	AA (Asn)	TT	CC (Gln)

The polymorphic allele of both patients was determined by DNA sequencing. ^aThe Table shows the particular bases at the indicated sites in the two alleles of each patient.

XPD protein containing the second, Leu485→Pro, alteration, which we predicted might be 'XP specific' and confer a relatively mild deficiency in NER. In order to analyse the effect of this allele independently of the Arg112→His allele, we employed a procedure that we have used successfully in previous work (14). We generated the analogous mutation in the orthologous *rad15* gene from *Schizosaccharomyces pombe*. We then introduced this gene on a plasmid into

S.pombe cells mutated in the *rad15* gene and analysed the ability of the Leu485→Pro altered protein firstly to rescue the lethal phenotype of a *rad15* deletion mutant, and secondly to increase the resistance to UV irradiation of the *rad15.P* point mutant. Unexpectedly, we found that the Leu485→Pro mutated *rad15* plasmid was completely inactive. Firstly, it was unable to rescue the lethality of the deletion strain. Secondly, in two separate transformants, it failed to complement the UV sensitivity of the *rad15.P* point mutant (Fig. 3D). Therefore, Leu485→Pro appeared to be a null mutation, encoding a completely inactive protein. In contrast, as shown previously (16), overexpression of plasmid containing the Arg112→His mutation resulted in substantial recovery of UV resistance (Fig. 3D). We confirmed by northern blotting and DNA sequencing that the plasmid-borne *rad15* gene was expressed at high levels and that there were no mutations in the *rad15* insert other than the one introduced to generate the Leu485→Pro alteration (data not shown). If we assume that these results can be extrapolated to the human situation, they suggest that XP38BR is likely to be functionally hemizygous for the Arg112→His allele, despite having clinical and cellular features quite different from those of other patients who are also functionally hemizygous at this allele.

Hairshaft analysis

In view of the unusual clinical features of both patients and the finding of a 'TTD specific' mutation in XP38BR, who had been diagnosed with XP, we conducted a more detailed analysis of the hairshafts from both individuals. Brittle sulfur-deficient hair with a 'tiger-tail' appearance under polarized light is the hallmark of TTD (4). The hair was not brittle in either of the patients, but it was sparse in XP38BR and she had an episode of hair loss at age 3. In XP189MA the hair was straw-like. Analysis under polarized light showed that the hairshafts from both patients did indeed manifest a tiger-tail appearance characteristic of TTD (Fig. 1E and F). Results of amino acid analyses on the hair are shown in Table 2. The defining hallmark of TTD is a >50% reduction of the sulfur content, with associated smaller decreases in Pro, and increases in Lys, Asp, Ala, Leu and Phe. The analysis of the hair of both XP189MA and XP38BR shows alterations when compared with the normal hair samples, but the changes are substantially less than those in bona fide TTD patients. By interpolation from the amino acid compositions of hair from normal and TTD donors, statistical analysis of the data from XP189MA and XP38BR can be interpreted as the hair having 66 and 37% TTD-like composition, respectively. In contrast, the hair from the XP complementation group D patient XP29BE with sun sensitivity, multiple skin cancers and mental retardation had only 5% TTD-like composition and did not have a tiger-tail appearance under polarized light (data not shown). This statistical analysis gives close to 100% normal or 100% TTD composition when applied in general to hairshaft samples. Therefore, the in-between levels in our patients represents a distinctly different entity. These analyses, together with the dysplastic nails and palmar-plantar hyperkeratosis in patient XP38BR, suggest that both patients, though not showing the full-blown phenotype, do have several of the characteristics of TTD.

Table 2. Hairshaft analysis

AA ^a	Control ^b	XP29BE ^c	TTD ^b	XP189MA	XP38BR
Lys	2.5	2.9	4.2	3.7	3.4
His	0.8	0.9	1.0	1.0	1.0
Arg	6.2	6.3	6.5	6.2	6.0
Asp	5.3	5.7	8.5	7.5	6.4
Thr	7.2	6.8	5.3	5.5	5.9
Ser	11.8	11.0	9.5	9.0	10.8
Glu	12.1	12.2	14.5	14.1	13.0
Pro	8.6	7.8	5.6	6.3	7.0
Gly	6.2	5.8	6.6	6.6	6.3
Ala	4.6	4.8	6.9	6.4	5.6
Val	5.8	5.8	6.5	6.2	6.0
Ile	2.6	2.8	3.8	3.6	3.2
Leu	6.1	6.7	9.4	8.5	7.6
Tyr	1.9	1.9	1.9	1.9	1.9
Phe	1.6	1.7	2.4	2.1	2.0
Cys	16.7	17.1	7.5	11.5	14.0
Sulfur	4.9	5.0	2.2	3.4	4.1
%TTD	0	5.6	100	65.9	36.9

The amino acid composition of the hairshafts of the patients was determined after acid hydrolysis.

^aCystine is reported as half-cystine from its molar equivalent cysteic acid. Methionine was omitted from the calculations.

^bControl composition taken from prior analysis of six normal young adults. TTD values are averages of one sample reported by Price *et al.* (36), three samples reported by Gillespie *et al.* (37) and four samples evaluated recently by E.Menefee and V.H.Price.

^cXP29BE is a classical XP patient (K.H.Kraemer, unpublished data).

DISCUSSION

Mutations in the *XPD* gene can result in the clinical phenotypes of either XP, TTD or the combined features of XP and CS. The patients that we describe in this paper are the first that have been reported with combined features of XP and TTD. In Table 3, we compare the characteristics of our patients with those of XP, TTD and CS patients. Neither patient had the full-blown phenotype of TTD. In particular, in neither case was the hair brittle. Nevertheless, in both patients, the hair did show the tiger-tail appearance under polarized light typical of TTD hairshafts, and the sulfur content of hairshaft proteins was substantially reduced, albeit to a lesser extent than in bona fide TTD individuals (Table 2). We have also considered these cases as possible further examples of XP with CS. Although XP189MA had the sunken eyes typical of a CS patient, the lack of retinal abnormalities, deafness, ataxia and brain calcification are not consistent with CS, although the patient is still very young. The ichthyosis and sulfur-deficient hair are cardinal features of TTD. With XP38BR, the obesity is clearly inconsistent with a diagnosis of CS, for which cachexia is a primary diagnostic feature. Normal hearing and lack of retinal abnormalities also do not support a diagnosis of CS. The dysplastic

Table 3. Clinical features of patients

	XP-D XP with neurologic disease (8)	CS	TTD	XP189MA	XP38BR
Sun-sensitivity	++	++	++	++	++
Increased freckling	++	-	-	+	+
Skin cancer	++	-	-	-	+
Ichthyosis	-	-	+	+	Palmar-plantar keratoderma
Brittle hair	-	-	+	-	-
Brittle nails	-	-	+	-	±
Tiger-tail appearance of hair	-	-	+	+	+
Sulfur-deficient hair	-	-	+	±	±
Progressive cognitive impairment	+	++	+	+	±
Neuronal degeneration	+	-	-	?	-
Sensorineural deafness	+	+	-	-	-
Pigmentary retinal degeneration	-	+	-	-	-
Loss of subcutaneous tissue	-	+	-	-	-
Demyelinating neuropathy	-	+	-/+	?	?
Dwarfism	+/-	++	++	++	+
Ataxia	+/-	+	-	-	-
Brain calcification	-	+	+/-	-	?

±, Mild defect; +/-, some but not all patients affected; ?, no data available.

nails, mild but significant sulfur deficiency are features associated with TTD, but again the hair is not brittle.

The causative mutations in XP189MA were both novel, one resulting in a protein truncation. XP189MA is unique in the XP-D group in having barely detectable levels of UDS. All other XP-D individuals, whether XP or TTD, have UDS levels between 10 and 45% of normal.

The XPD protein with the alteration Leu485→Pro corresponding to one mutated allele in XP38BR is completely inactive, at least in the fission yeast orthologue. The second allele contains a mutation, resulting in Arg112→His, which is the most commonly mutated allele in TTD patients (9). Therefore, the mild XP phenotype in this patient is unexpected. However, the finding of a single mutation resulting in more than one phenotype has been reported in other human genetic diseases. For example, we recently identified two families with affected individuals homozygous for the identical mutation in the *CSB* gene. In one family the proband had classical CS, in the other a severe form of XP (24). A further unexpected finding was that the levels of repair of UV damage and cell survival in XP38BR (Fig. 2) were substantially higher than found for other patients mutated at this site (16,19).

There are several possible explanations for the perplexing findings with XP38BR: (i) It is possible that XPD with Leu485→Pro does have activity in human cells unlike the orthologue in *S.pombe*. In view of the high sequence conservation between yeast and man, we consider this unlikely. (ii) Reports in the literature have suggested that different polymorphic alleles in the *XPD* gene can affect the proneness to skin cancer and DNA repair in the general population (25–27). In these studies the Lys751 allele was associated with greater

skin cancer risk than the Gln751 allele. Since XP38BR has the Gln751 allele, and the two patients have completely different polymorphic alleles, it is unlikely that the particular polymorphic alleles in the two patients can account for their unusual features. (iii) We consider the most likely explanation to be that XP38BR contains an as yet unidentified modifying mutation in another gene that partially suppresses the defects in both transcription and NER that are usually associated with Arg112→His mutations. We propose that the milder putative transcription defects in XP38BR result in only partial TTD features. We have previously suggested that it is the transcriptional defect in TTD that prevents the development of the skin abnormalities that are associated with XP patients with similar defects in NER (16). Consistent with this idea, the proposed milder defect in transcription in XP38BR permits the development of the skin abnormalities characteristic of XP, albeit again with a mild phenotype. We propose that a similar explanation pertains for the mutation in XP189MA. Obviously, further experimentation is required to unravel the cause of these paradoxical findings.

Mutations in the *XPD* gene are associated with a complex variety of different clinical features. Apart from the clearly defined syndromes of XP, TTD and XP/CS, there is within these syndromes a range of severity both with respect to clinical features and cellular sensitivity to DNA damage. Recently, a family with cerebro-oculo-facio-skeletal syndrome (COFS), a disorder with many similarities to CS has been assigned to the XP-D group (28). The two patients reported in this paper add yet another layer of complexity that has not been reported previously, namely combined features of XP and TTD with intermediate levels of sulfur deficiency in the hairshafts. The

picture that is now emerging is that mutations in the *XPD* gene can be associated not only with clinical features of XP or TTD, but also with a spectrum of combinations of features found in XP, CS and TTD.

MATERIALS AND METHODS

Fibroblast cultures were established from skin biopsies taken from the patients with informed consent, and grown in Eagle's MEM with 15% fetal calf serum. Cell survival was determined by measuring the colony-forming ability of the fibroblasts following exposure to graded doses of UV-C light (29). UDS was assessed by measuring the incorporation of ³H-thymidine into DNA in non-dividing cells. The cells were grown for 3 days in medium containing 0.5% fetal calf serum, UV-C irradiated and incubated in the presence of hydroxyurea and ³H-thymidine for 2 h (30). RNA synthesis was measured as incorporation of ³H-uridine during a 4 h labelling period 24 h after UV-C irradiation of non-dividing cells (31). Complementation group assignment was carried out by fusing the test cells with other XP cell strains from different complementation groups. The fused culture was UV-irradiated and UDS was measured in heterokaryons by autoradiography (32).

Apoptosis was quantified by measuring the sub-G1 cell fraction by flow cytometry. Fibroblast cell strains were irradiated in exponential growth phase and at various times after irradiation, attached cells were trypsinized and collected together with detached cells, by centrifugation. The cell pellets were washed with phosphate-buffered saline (PBS), fixed in 70% ethanol and stored at -20°C. Cells were incubated with RNase (20 mg/ml) in PBS for 30 min at 37°C and stained with propidium iodide (70 µg/ml) for 30 min at 37°C prior to analysis in a Coulter EPICS Profile II cytometer. Cell cycle distributions were calculated with Multicycle AV software (Phoenix Flow Systems, Inc., San Diego, CA). Fluorescence values significantly below the normal G1 values (Sub-G1) were taken as an indication of apoptosis (33,34). All experiments were carried out at least twice for each cell type studied.

Molecular analysis of mutations was performed using RT-PCR and direct sequencing as described previously (6,18). RNA was extracted from fibroblast cultures using TRIZOL reagent (Life Technologies, Paisley, UK). Total RNA was reverse-transcribed with a first-strand DNA synthesis kit (Amersham-Pharmacia, Little Chalfont, UK) and the *XPD* cDNA amplified by PCR in three fragments. The PCR products were sequenced using the ThermoSequenase radiolabelled terminator cycle sequencing kit (Amersham-Pharmacia) and ³³P-labelled dideoxynucleotides. Construction of mutant *rad15* plasmids and their analysis in *S.pombe* have been described earlier (14,16).

The amino acid composition of hairshafts was determined following oxidation by performic acid and hydrolysis by HCl. The percentage of TTD-type components was estimated by a least-squares procedure that finds the best combination of control and TTD compositions to duplicate the sample composition (35).

ACKNOWLEDGEMENTS

We are grateful to Susan Harcourt and Steven Coade for the data in Figure 2A. The work was supported in part by EC-FP5 contract QLG1-1999-0181 to A.R.L. and M.S., by the Emmy

Noether Scholarship BE 2005/2-1 of the Deutsche Forschungsgemeinschaft to M.B. and by an Associazione Italiana per le Ricerche sul Cancro grant to M.S.

REFERENCES

- Kraemer, K.H., Lee, M.-M., Andrews, A.D. and Lambert, W.C. (1994) The role of sunlight and DNA repair in melanoma and non-melanoma skin cancer: the xeroderma pigmentosum paradigm. *Arch. Dermatol.*, **130**, 1018-1021.
- Bootsma, D., Kraemer, K.H., Cleaver, J.E. and Hoeijmakers, J.H.J. (1998) Nucleotide excision repair syndromes: xeroderma pigmentosum, Cockayne syndrome, and trichothiodystrophy. In Vogelstein, B. and Kinzler, K.W. (eds), *The Genetic Basis of Human Cancer*. McGraw-Hill, New York, pp. 245-274.
- Berneburg, M. and Lehmann, A.R. (2001) Xeroderma pigmentosum and related disorders: defects in DNA repair and transcription. *Adv. Genet.*, **43**, 71-102.
- Itin, P.H., Sarasin, A. and Pittelkow, M.R. (2001) Trichothiodystrophy: update on the sulfur-deficient brittle hair syndromes. *J. Am. Acad. Dermatol.*, **44**, 891-920.
- Stefanini, M., Lagomarsini, P., Giliani, S., Nardo, T., Botta, E., Peserico, A., Kleijer, W.J., Lehmann, A.R. and Sarasin, A. (1993) Genetic heterogeneity of the excision repair defect associated with trichothiodystrophy. *Carcinogenesis*, **14**, 1101-1105.
- Broughton, B.C., Thompson, A.F., Harcourt, S.A., Vermeulen, W., Hoeijmakers, J.H.J., Botta, E., Stefanini, M., King, M., Weber, C., Cole, J. et al. (1995) Molecular and cellular analysis of the DNA repair defect in a patient in xeroderma pigmentosum complementation group D with the clinical features of xeroderma pigmentosum and Cockayne syndrome. *Am. J. Hum. Genet.*, **56**, 167-174.
- Takayama, K., Salazar, E.P., Lehmann, A.R., Stefanini, M., Thompson, L.H. and Weber, C.A. (1995) Defects in the repair and transcription gene *ERCC2* in the cancer-prone disorder xeroderma pigmentosum. *Cancer Res.*, **55**, 5656-5663.
- Rapin, I., Lindenbaum, Y., Dickson, D.W., Kraemer, K.H. and Robbins, J.H. (2000) Cockayne syndrome and xeroderma pigmentosum: DNA repair disorders with overlaps and paradoxes. *Neurology*, **55**, 1442-1449.
- Lehmann, A.R. (2001) The xeroderma pigmentosum group D (*XPD*) gene: one gene, two functions, three diseases. *Genes Dev.*, **15**, 15-23.
- Schaeffer, L., Roy, R., Humbert, S., Moncollin, V., Vermeulen, W., Hoeijmakers, J.H.J., Chambon, P. and Egly, J.-M. (1993) DNA repair helicase: a component of BTF2 (TFIIH) basic transcription factor. *Science*, **260**, 58-63.
- Schaeffer, L., Moncollin, V., Roy, R., Staub, A., Mezzina, M., Sarasin, A., Weeda, G., Hoeijmakers, J.H.J. and Egly, J.M. (1994) The ERCC2/DNA repair protein is associated with the class II BTF2/TFIIH transcription factor. *EMBO J.*, **13**, 2388-2392.
- Hoeijmakers, J.H.J., Egly, J.-M. and Vermeulen, W. (1996) TFIIH: a key component in multiple DNA transactions. *Curr. Opin. Genet. Dev.*, **6**, 26-33.
- Bootsma, D. and Hoeijmakers, J.H.J. (1993) Engagement with transcription. *Nature*, **363**, 114-115.
- Taylor, E.M., Broughton, B.C., Botta, E., Stefanini, M., Sarasin, A., Jaspers, N.G.J., Fawcett, H., Harcourt, S.A., Arlett, C.F. and Lehmann, A.R. (1997) Xeroderma pigmentosum and trichothiodystrophy are associated with different mutations in the *XPD* (*ERCC2*) repair/transcription gene. *Proc. Natl Acad. Sci. USA*, **94**, 8658-8663.
- de Boer, J., de Wit, J., van Steeg, H., Berg, R.J.W., Morreau, H., Visser, P., Lehmann, A.R., Duran, M., Hoeijmakers, J.H.J. and Weeda, G. (1998) A mouse model for the basal transcription/ DNA repair syndrome trichothiodystrophy. *Mol. Cell*, **1**, 981-990.
- Berneburg, M., Clingen, P.H., Harcourt, S.A., Lowe, J.E., Taylor, E.M., Green, M.H.L., Krutmann, J., Arlett, C.F. and Lehmann, A.R. (2000) The cancer-free phenotype in trichothiodystrophy is unrelated to its repair defect. *Cancer Res.*, **60**, 431-438.
- Queille, S., Drougard, C., Sarasin, A. and Daya-Grosjean, L. (2001) Effects of *XPD* mutations on UV-induced apoptosis in relation to skin cancer proneness in repair deficient syndromes. *J. Invest. Dermatol.*, in press.
- Broughton, B.C., Steingrimsdottir, H., Weber, C. and Lehmann, A.R. (1994) Mutations in the xeroderma pigmentosum group D DNA repair gene in patients with trichothiodystrophy. *Nat. Genet.*, **7**, 189-194.

19. Botta, E., Nardo, T., Broughton, B.C., Marinoni, S., Lehmann, A.R. and Stefanini, M. (1998) Analysis of mutations in the *XPD* gene in Italian patients with trichothiodystrophy: site of mutation correlates with repair deficiency but gene dosage appears to determine clinical severity. *Am. J. Hum. Genet.*, **63**, 1036–1048.
20. Weber, C.A., Salazar, E.P., Stewart, S.A. and Thompson, L.H. (1990) *ERCC-2*: cDNA cloning and molecular characterization of a human nucleotide excision repair gene with high homology to yeast RAD3. *EMBO J.*, **9**, 1437–1448.
21. Sung, P., Bailly, V., Weber, C., Thompson, L.H., Prakash, L. and Prakash, S. (1993) Human xeroderma pigmentosum group D gene encodes a DNA helicase. *Nature*, **365**, 852–855.
22. Broughton, B.C., Steingrimsdottir, H. and Lehmann, A.R. (1996) Five polymorphisms in the coding sequence of the xeroderma pigmentosum group D gene. *Mutat. Res.*, **362**, 209–211.
23. Shen, M.R., Jones, I.M. and Mohrenweiser, H. (1998) Non-conservative amino acid substitution variants exist at polymorphic frequency in DNA repair genes in healthy humans. *Cancer Res.*, **58**, 604–608.
24. Colella, S., Nardo, T., Botta, E., Lehmann, A.R. and Stefanini, M. (2000) Identical mutations in the *CSB* gene associated with either Cockayne syndrome or DeSanctis-Cacchione variant of xeroderma pigmentosum. *Hum. Mol. Genet.*, **9**, 1171–1175.
25. Dybdahl, M., Vogel, U., Frentz, G., Wallin, H. and Nexø, B.A. (1999) Polymorphisms in the DNA repair gene *XPB*: correlations with risk and age at onset of basal cell carcinoma. *Cancer Epidemiol. Biomarkers Prev.*, **8**, 77–81.
26. Lunn, R.M., Helzlsouer, K.J., Parshad, R., Umbach, D.M., Harris, E.L., Sanford, K.K. and Bell, D.A. (2000) *XPB* polymorphisms: effects on DNA repair proficiency. *Carcinogenesis*, **21**, 551–555.
27. Tomescu, D., Kavanagh, G., Ha, T., Campbell, H. and Melton, D.W. (2001) Nucleotide excision repair gene *XPB* polymorphisms and genetic predisposition to melanoma. *Carcinogenesis*, **22**, 403–408.
28. Graham, J.M., Anyane-Yeboa, K., Raams, A., Appeldoorn, E., Kleijer, W.J., Garritsen, V.H., Busch, D., Edersheim, T.G. and Jaspers, N.G. (2001) Cerebro-oculo-facio-skeletal syndrome with a nucleotide excision-repair defect and a mutated *XPB* gene, with prenatal diagnosis in a triplet pregnancy. *Am. J. Hum. Genet.*, **69**, 291–300.
29. Arlett, C.F., Harcourt, S.A., Cole, J., Green, M.H.L. and Anstey, A.V. (1992) A comparison of the response of unstimulated and stimulated T-lymphocytes and fibroblasts from normal, xeroderma pigmentosum and trichothiodystrophy donors to the lethal action of UV-C. *Mutat. Res.*, **273**, 127–135.
30. Lehmann, A.R. and Stevens, S. (1980) A rapid procedure for measurement of DNA repair in human fibroblasts and for complementation analysis of xeroderma pigmentosum cells. *Mutat. Res.*, **69**, 177–190.
31. Lehmann, A.R., Thompson, A.F., Harcourt, S.A., Stefanini, M. and Norris, P.G. (1993) Cockayne's syndrome: correlation of clinical features with cellular sensitivity of RNA synthesis to UV-irradiation. *J. Med. Genet.*, **30**, 679–682.
32. Stefanini, M., Giliani, S., Nardo, T., Marinoni, S., Nazzaro, R., Rizzo, R. and Trevisan, G. (1992) DNA repair investigations in nine Italian patients affected by trichothiodystrophy. *Mutat. Res.*, **273**, 119–125.
33. Nicoletti, I., Migliorati, G., Pagliacci, M.C., Grignani, F. and Riccardi, C. (1991) A rapid and simple method for measuring thymocyte apoptosis by propidium iodide staining and flow cytometry. *J. Immunol. Methods*, **139**, 271–279.
34. Darzynkiewicz, Z., Bruno, S., Del Bino, G., Gorczyca, W., Hotz, M.A., Lassota, P. and Traganos, F. (1992) Features of apoptotic cells measured by flow cytometry. *Cytometry*, **13**, 795–808.
35. Menefee, E. and Friedman, M. (1985) Estimation of structural components of abnormal human hair from amino acid analyses. *J. Protein Chem.*, **4**, 333–341.
36. Price, V.H., Odom, R.B., Ward, W.H. and Jones, F.T. (1980) Trichothiodystrophy. Sulfur-deficient brittle hair as a marker for a neuroectodermal symptom complex. *Arch. Dermatol.*, **116**, 1375–1384.
37. Gillespie, J.M., Marshall R.C. and Rogers, M. (1988) Trichothiodystrophy—biochemical and clinical studies. *Australas. J. Dermatol.*, **29**, 85–93.

